

BONES OF THE APPENDICULAR SKELETON

The appendicular skeleton is composed of the 126 bones of the appendages and the pectoral and pelvic girdles, which attach the limbs to the axial skeleton. Although the bones of the upper and lower limbs differ in their functions and mobility, they have the same fundamental plan – each limb is composed of three major segments connected by movable joints.

UPPER LIMB

Thirty-two (32) separate bones form the bony framework of each upper limb. Each of these bones may be described regionally as a bone of the pectoral girdle, arm, forearm, or hand (Figure 1).

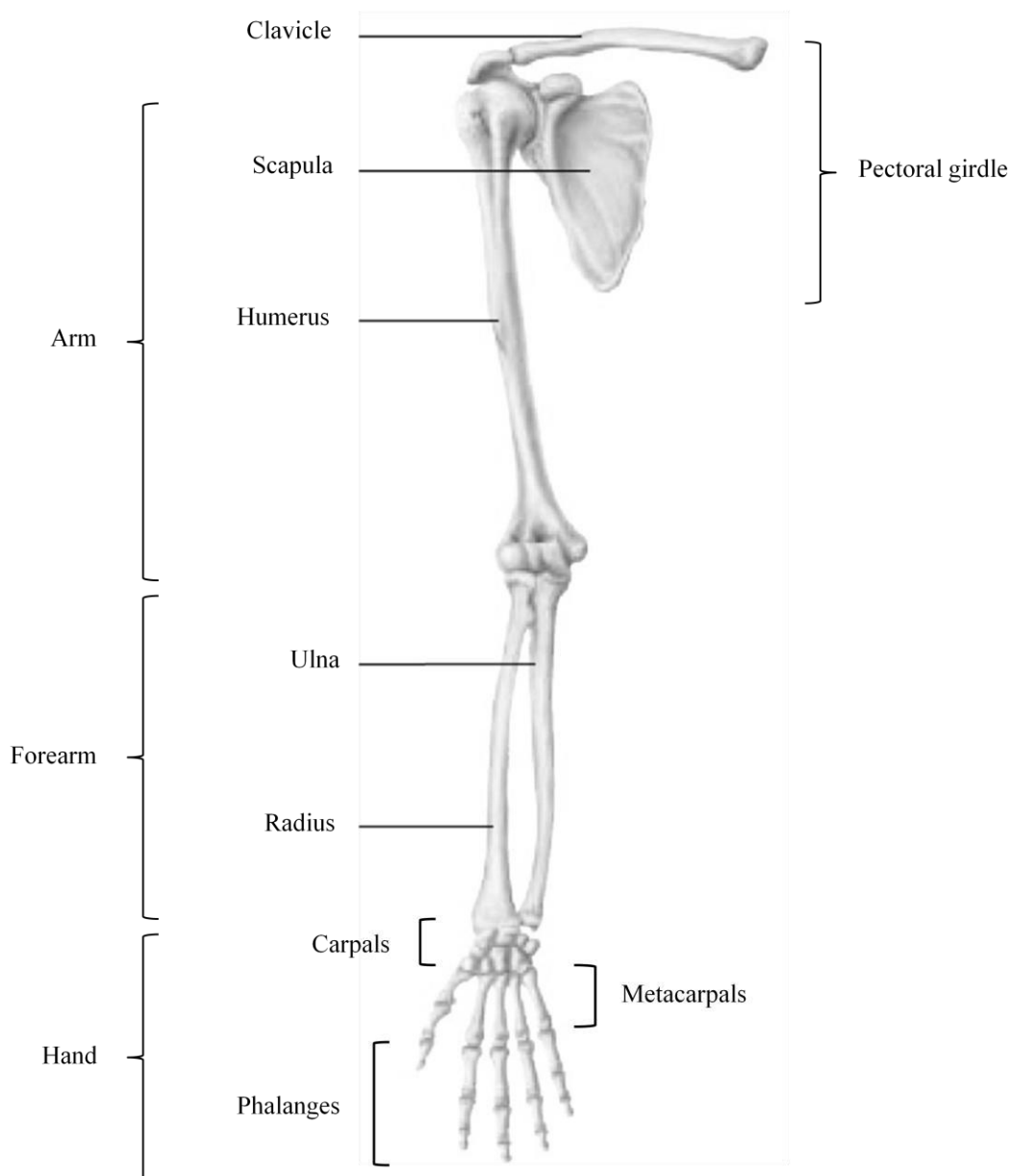


Figure 1: Bones of the upper limb

Pectoral (Shoulder) Girdle

The paired pectoral girdles each consist of two bones, the anterior clavicle and the posterior scapula. The shoulder girdles function to attach the upper limbs to the axial skeleton. In addition, the bones of the shoulder girdles serve as attachment points for many trunk and neck muscles.

The pectoral girdle is exceptionally light and allows the upper limb a degree of mobility not seen anywhere else in the body. This is due to multiple factors including:

- 1) The sternoclavicular joints are the only site of attachment of the shoulder girdles to the axial skeleton.
- 2) The relative looseness of the scapular attachment allows it to slide back and forth against the thorax with muscular activity.
- 3) The bone connection between the humerus and scapula is shallow, and does little to stabilize the shoulder joint.

A. **Clavicle:** A slender, doubly-curved bone that joins the sternum to the scapula (Figure 2); serves as an anterior brace, or strut, to hold the arm away from the top of the thorax.

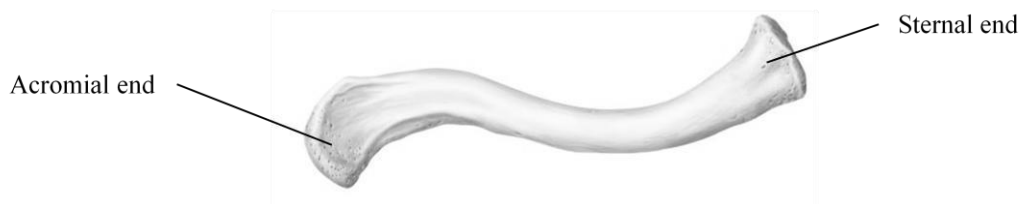

Figure 2: Right clavicle, superior view

Landmarks / Markings:

- **Sternal end:** Rounded terminus of clavicle; articulates with the sternal manubrium.
- **Acromial end:** Flattened terminus of clavicle; articulates with the scapula to form part of the shoulder joint.

B. **Scapula:** Thin, triangular flat bone; lies on the dorsal surface of the rib cage (Figure 3); serves as the attachment point for the arm.

Borders / angles:

- **Superior border:** Short, sharp border that forms the upper margin of the scapula when articulated with the axial skeleton.
- **Medial (vertebral) border:** Border which parallels the vertebral column when articulated with the axial skeleton; joins with superior border at the **superior angle**.
- **Lateral (axillary) border:** The thick border that abuts the armpit when articulated with the axial skeleton; joins with superior border at the **lateral angle** and joins with medial border at the **inferior angle**.

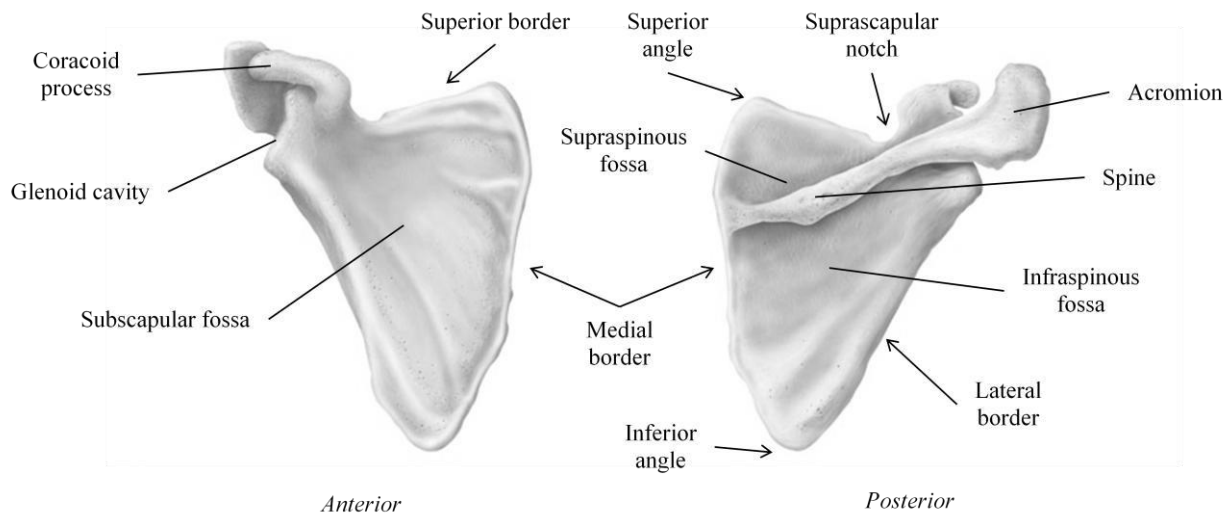


Figure 3: Right scapula, anterior and posterior views

Landmarks / Markings:

- **Glenoid cavity (fossa):** Small, shallow depression superior to the lateral border, near the lateral angle; articulates with humerus of the arm.
- **Spine:** Prominent ridge rising from the upper posterior surface of the scapula; site of muscle attachment.
- **Acromion:** Enlarged, roughened triangular structure projecting projection off the lateral end of the scapular spine; articulates with the acromial end of the clavicle.
- **Coracoid process:** Beak-like structure projecting anteriorly from the superior scapular border; site of muscle attachment.

- **Suprascapular notch:** Shallow groove in the superior border of the scapula at the base of the coracoid process; passageway for nerves.
- **Supraspinous fossa:** Deep depression superior to the spine on the posterior surface of the scapula; site of muscle attachment.
- **Infraspinous fossa:** Shallow depression inferior to the spine on the posterior surface of the scapula; site of muscle attachment.
- **Subscapular fossa:** Shallow depression formed by the entire anterior scapular surface; site of muscle attachment.

ARM

The arm consists of a single bone, the humerus (Figure 4). The largest and longest bone of the upper limb, it articulates with the scapula at the shoulder and with the radius and ulna (forearm bones) at the elbow.

A. Humerus:

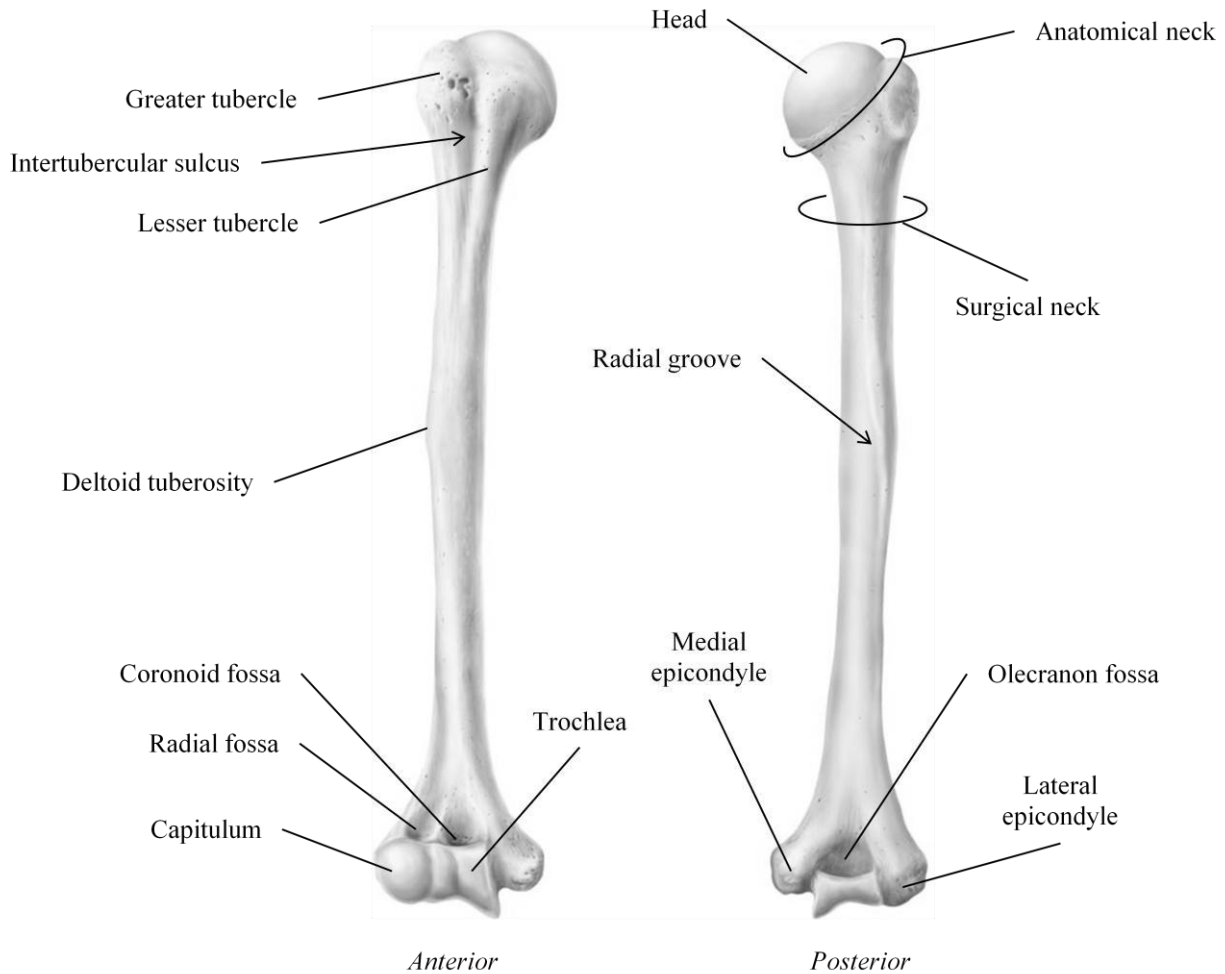


Figure 4: Right humerus, anterior and posterior views

Landmarks / Markings:

- **Head:** Smooth, hemispherical projection at the proximal end of the humerus; articulates with glenoid cavity of scapula.
- **Anatomical neck:** Slight constriction just distal to the head of the humerus.
- **Greater Tubercle:** Large prominence just distal to the anatomical neck on the lateral surface of the humerus; site of muscle attachment.

- **Lesser Tubercle:** Small prominence just distal to the anatomical neck on the medial surface of the humerus; site of muscle attachment.
- **Intertubercular sulcus:** Shallow groove between lesser and greater tubercles; guides tendon.
- **Surgical neck:** Constricted region of the humerus just distal to the tubercles; common site of bone fracture.
- **Deltoid tuberosity:** V-shaped rough region on the lateral aspect of the humerus about midway down the shaft; site of muscle attachment.
- **Radial groove:** A shallow depression running obliquely down the posterior aspect of the humerus shaft; nerve passageway.
- **Trochlea:** Medial spool-shaped structure on the distal end of the humerus; articulates with ulna of the forearm.
- **Capitulum:** Lateral ball-like structure on the distal end of the humerus; articulates with radius of the forearm.
- **Medial epicondyle:** Small outward projection flanking trochlea; site of muscle attachment.
- **Lateral epicondyle:** Small outward projection flanking capitulum; site of muscle attachment.
- **Coronoid fossa:** Large, shallow depression superior to the trochlea on the anterior surface of the humerus; receives corresponding process from ulna when elbow flexes / extends.
- **Radial fossa:** Small, shallow depression lateral to the coronoid fossa; receives head of radius when elbow flexes.
- **Olecranon fossa:** Large, deep depression superior to the trochlea on the posterior surface of the humerus; anchors corresponding process from ulna to form elbow joint.

Forearm

Two parallel bones, the radius and the ulna, form the forearm (Figure 5). Their proximal ends articulate with the humerus and their distal ends articulate with the wrist bones.

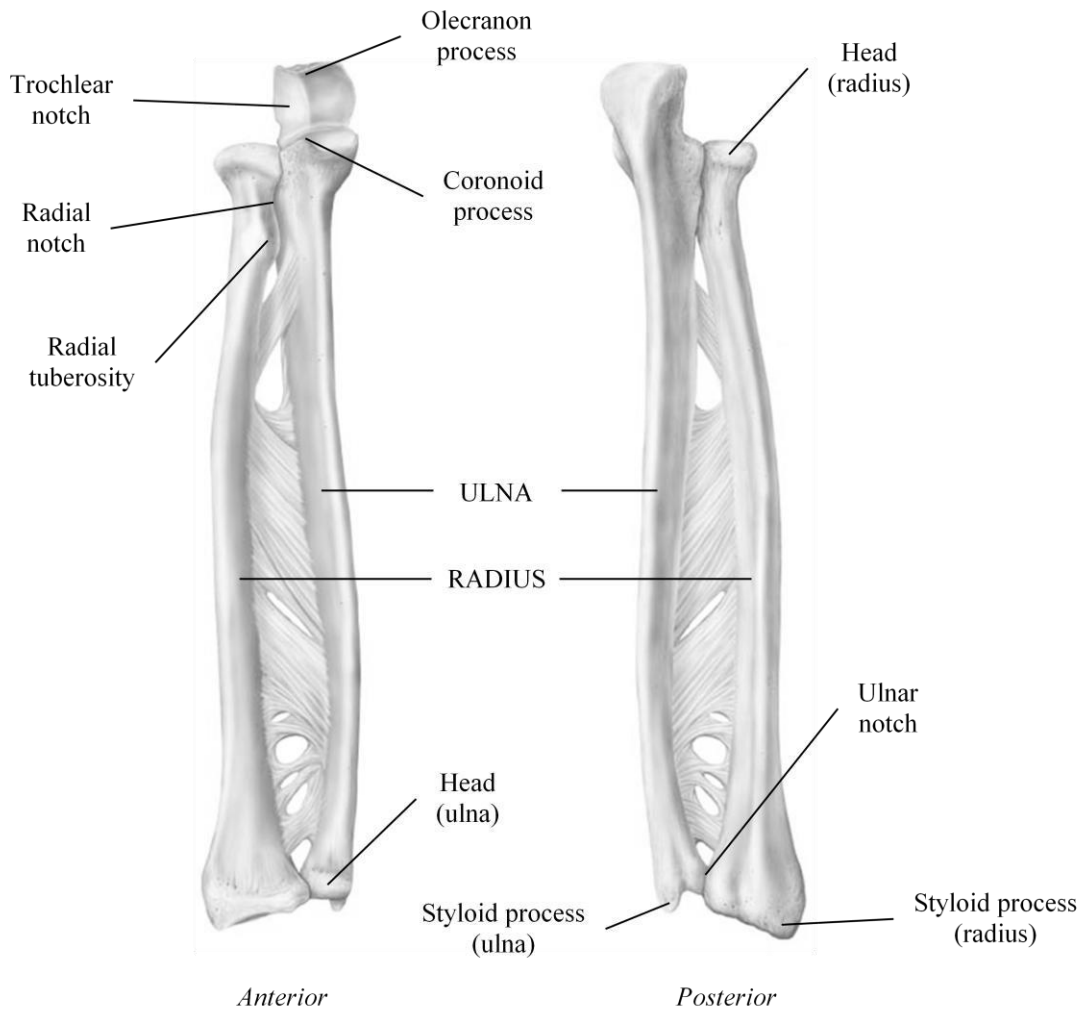


Figure 5: Right ulna and radius, anterior and posterior views

- A. **Ulna:** Long, slender bone with a hook at the proximal end that forms the elbow joint with the humerus; lies medially in the forearm when the body is in anatomical position.

Landmarks / Markings:

- **Olecranon process:** Large protuberance on the proximal end of the ulna; forms the upper portion of the hook that articulates with the trochlea of the humerus.

- **Coronoid process:** Small process located just distal to the olecranon process; forms the lower portion of the hook that articulates with the trochlea of the humerus.
- **Trochlear notch:** Deep concavity found between the olecranon process and coronoid process; 'grips' trochlea to form elbow joint.
- **Radial notch:** Small depression on the lateral side of the coronoid process; articulates with head of radius.
- **Head:** Knob-like structure and the distal end of the ulna; articulates with wrist bone.
- **Styloid process:** Pointed process medial to the head of the ulna; site of ligament attachment.

B. **Radius:** Long bone that is thin at its proximal end and wide at its distal end; lies laterally in the forearm when the body is in anatomical position.

Landmarks / Markings:

- **Head:** Wheel-shaped proximal end of radius; articulates with capitulum of humerus and radial notch of ulna.
- **Radial tuberosity:** Rough projection just inferior to the head of the radius; site of muscle attachment.
- **Ulnar notch:** Medial shallow depression on the distal end of the radius; articulates with the ulna.
- **Styloid process:** Pointed process lateral to the ulnar notch; site of ligament attachment.

Hand

The skeleton of the hand includes the bones of the carpus (wrist); the bones of the metacarpus (palm), and the bones of the phalanges (fingers) (Figure 6).

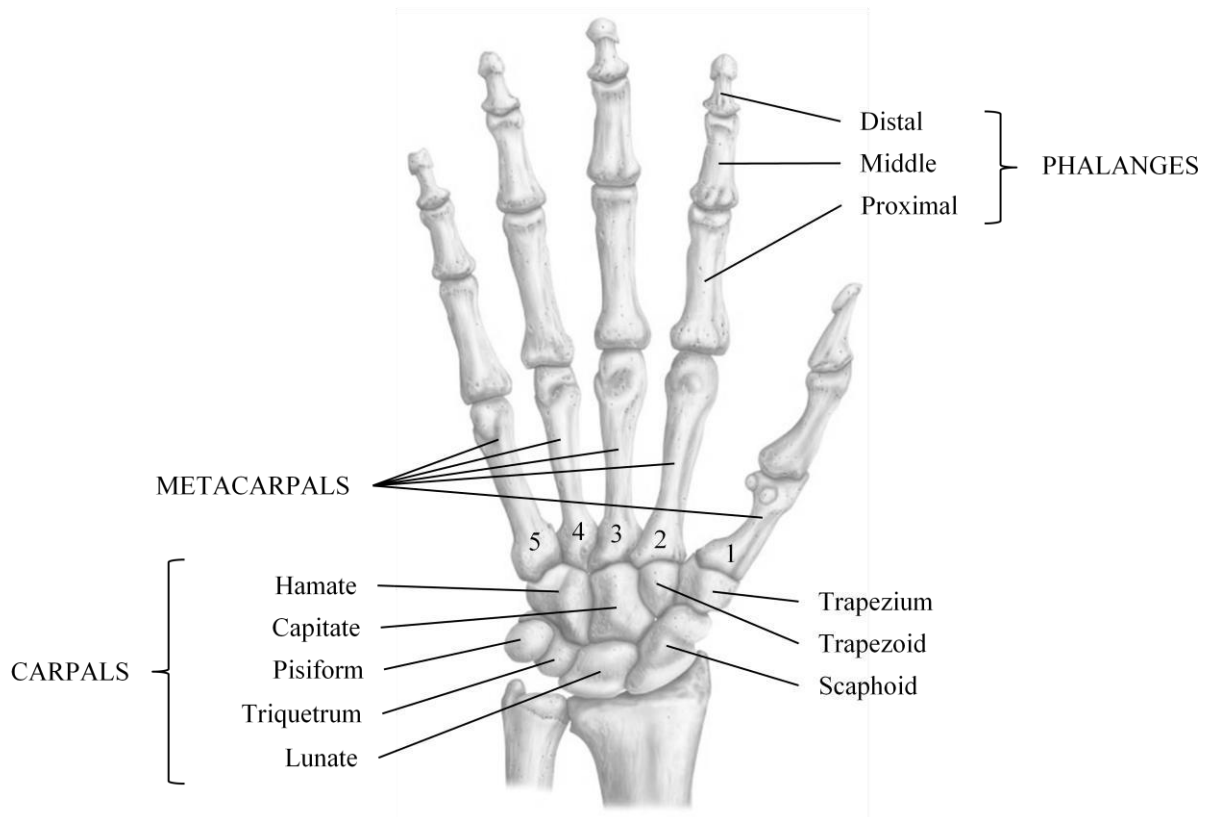


Figure 6: Right hand, anterior view

A. **Carpals** (wrist): Eight (8) marble-size short bones closely united by ligaments; quite flexible due to gliding movements between bones.

- | | | |
|----------------------|-------------------------------------|---------------------|
| 1) Scaphoid | } Closely articulate
with radius | 5) Trapezium |
| 2) Lunate | | 6) Trapezoid |
| 3) Triquetrum | | 7) Capitate |
| 4) Pisiform | | 8) Hamate |

- B. **Metacarpals:** Five (5) small long bones radiating from the wrist like spokes; numbered **1 – 5** from the thumb to the little finger.
- C. **Phalanges:** Fourteen (14) miniature long bones that form the fingers; numbered 1 – 5 from the thumb (**pollex**) to the little finger.
- 1) **Proximal phalange (1 – 5)**
 - 2) **Middle phalange (2 – 5)**
 - 3) **Distal phalange (1 – 5)**

CHECKLIST: BONES / MARKINGS OF THE UPPER LIMB

BONES OF THE PECTORAL GIRDLE:

Clavicle*

- Sternal end
- Acromial end

Scapula*

- Superior / medial / lateral border
- Superior / lateral / inferior angle
- Glenoid cavity (fossa)
- Spine
- Acromion
- Coracoid process
- Suprascapular notch
- Suprascapular fossa
- Infraspinous fossa
- Subscapular fossa

BONE OF THE ARM:

Humerus*

- Head
- Anatomical / surgical neck
- Greater / lesser tubercle
- Deltoid tuberosity
- Radial groove
- Trochlea
- Capitulum
- Medial /lateral epicondyle
- Coronoid fossa
- Radial fossa
- Olecranon fossa

BONES OF THE FOREARM:

Ulna*

- Olecranon process
- Coronoid process
- Trochlear notch
- Radial notch
- Head
- Styloid process

Radius*

- Head
- Radial tuberosity
- Ulnar notch
- Styloid process

BONES OF THE WRIST / HAND:

- Scaphoid**
 - Lunate**
 - Triquetrum**
 - Pisiform**
 - Trapezium**
 - Trapezoid**
 - Capitate**
 - Hamate**
 - Metacarpals (1 – 5)**
 - Phalanges**
- } **Carpals (8)**

- Proximal, middle, distal
- Pollex

* Need to be able to identify bone from right vs. left side of body

